

# **SURGICAL ANATOMY OF THE SERPENTINE (COLUBRIDAE AND BOIDAE) KIDNEY WITH PARTICULAR REGARD TO SURGICAL NEPHRECTOMY**

**Stephen J. Divers, BSc(Hons), BVetMed, Guin Ness, CertZooMed, CBiol,  
MIBiol, MRCVS\***

**Martin P.C. Lawton, MIBiol DZooMed (Reptilian) FRCVS, RCVS Specialist in  
Exotic Animal Medicine**

*Exotic Animal Centre  
12 Fitzillian Avenue  
Harold Wood  
Romford  
Essex RM3 0QS  
England*

**Jeanette Wyneken, PhD**

*Department of Biological Sciences  
Florida Atlantic University  
777 Glades Road  
Post Office Box 3091  
Boca Raton, Florida  
USA*

**Abstract:** The kidneys of common terrestrial pet snakes (Colubridae, Boidae) are located within the caudal third of the coelomic cavity. They are paired, elongated organs with segmental lobules. There are occasions when surgical removal of a single diseased kidney is required. This paper aims to review the anatomy of the serpentine kidney and provide details on a technique for nephrectomy.

**Key words:** snake, serpentes, kidney, anatomy, nephrectomy

## **Gross anatomy of the renal system of snakes**

The renal system of snakes consists of paired elongate kidneys, ureters, renal arteries and renal veins. Gonadal ducts are closely associated with the kidneys. The kidneys are located dorsolaterally in the posterior portion of the body, anterior to the cloaca (Kellcott, 1898). While the gonads and adrenal glands lie within the peritoneal cavity, the kidneys are retroperitoneal (located between a peritoneal membrane and the muscular body wall).

In the vast majority of snakes the right kidney is located more anteriorly than the left (Fox, 1977, Chiodini, *et al*, 1982). In pythons and boas, the kidneys can be located by using the ventral scales as landmarks or a percentage range of the snout-vent length (Jackson and Lawton, 1992). The kidney on the left is found between ventral scales 45 - 65 or 74 - 82% of snout-length and between ventral scales 55-78 or 69-77% on the right (where the anal plate is scale 1 and snout-vent length % is based on the length from the anterior-most rostrum to the cloaca). The

positions of the kidneys (as well as other organs) of boids, elapids, colubrids, and crotalids are summarized by McCracken (1999). The anterior-most border of the right kidney may extend just beyond the gallbladder in some species (Beddard, 1906). The kidneys may be symmetrically located in a few species of snakes (e.g. burrowing pythons, *Calabaria* spp., Underwood, 1967). The lobular kidneys are dark pink to reddish purple. The number of lobes varies with taxon (Fox, 1977).

In most snakes, the kidneys are flattened on their ventral surface and convex on their dorsal and neural surfaces (Kellicott, 1898). They end anterior to the cloaca. Snakes lack a urinary bladder so nitrogenous wastes travel from the collecting tubules of the kidneys, through the ureters, to the posterior and dorsal part of the cloaca (the urodeum). Expanded terminal ends of the ureters act as valves to insure unidirectional flow.

In some hatchling snakes, for example anacondas, *Eunectes* spp., the kidney has an anterior portion that disappears with age. This is a consequence of the way in which reptilian kidneys develop; that anterior portion is a remnant of the mesonephros while the posterior (persistent) portion is a metanephros (a typical reptilian kidney). The mesonephric portion becomes part of the vas deferens in males and disappears in females. The anterior kidney of hatchlings is distinguishable from the adrenal gland by its color and texture. The elongate yellow or pink adrenal glands lack lobes and are found medial to (and in some cases embedded in the midbody of) the mesonephric kidneys (Beddard, 1906).

In males, the vas deferens lies between the ureter and the dorsal aorta and is attached to the peritoneal surface of the kidney. Like the ureters, the vas deferens are paired structures. Each is a highly coiled white tube that extends from the lateral border of the ureter where it enters the cloaca, anteriorly beyond the kidney to the testis. Some sexually mature male snakes exhibit a 'sexual segment' hypertrophy of the renal epithelial cells that line the caudal portion of the distal convoluted tubules. This seasonal hypertrophy is associated with peak testicular activity and, although usually appreciable histologically, it may result in noticeable renal enlargement in some species. The kidneys of females do not differ in their location from those of males; however, the ureters enter the cloaca in a slightly different position. Passing posteriorly, each enters the posterodorsal cloaca, anterior to the slit-like openings of the oviducts (Kellicott, 1898). The oviducts are suspended via a mesentery arising medial to the kidney and lateral to the dorsal aorta.

Snakes have a renal portal system. Blood arrives at the kidneys from the dorsal aorta via four to five renal arteries that quickly give off many small branches within the body of each kidney. Blood returning from the caudal part of the snake and can enter the kidneys via afferent renal veins from the caudal vein. Both sources supply capillaries to the renal tubules. Venues leave the capillary beds associated with the renal tubules and coalesce to form the efferent renal portal veins which drain into the post cava (ascending vena cava). Blood returning from the caudal vein may also bypass the kidneys by shunting from the afferent renal veins to the mesenteric vein or, in some pythons species, e.g. *Python sebae* and *P. molurus*, via branches to the abdominal vein (Holtz, 1999).

### Clinical investigation

When dealing with a unilateral nephrectomy in the snake the reason for presentation is generally the presence of a gross swelling in the caudal third of the snake. Palpation will confirm the

presence of a soft tissue intracoelomic mass. Radiography can be used to differentiate between soft tissue masses and fecal material or eggs, but it seldom provides a great deal more information than palpation. Ultrasonography can be useful to determine any cystic structures or tissue heterogeneity.

Blood biochemistry seldom demonstrates any clinically apparent renal compromise when a second normal kidney is present. Only in cases of severe generalized renal disease will renal biochemical changes become obvious. Hematology may be useful to identify inflammatory and infectious reactions associated with unilateral disease.

In many cases the diagnosis of unilateral renal disease is made during the exploratory coeliotomy of a caudal coelomic mass.

### **Surgical nephrectomy**

Following the decision to surgically intervene, the snake is anesthetized and aseptically prepared for coeliotomy in a standard manner (Lawton and Stoakes, 1992, Bennett and Mader, 1996). The exact position of the surgical incision is governed by the position of greatest distension. The skin incision is made in the interscaler skin between the first and second or second and third lateral scale rows, taking care to avoid cutting through scales. The subcutaneous tissues are bluntly dissected until the ribs are located. Entry into the coelomic cavity is made just medial to the ribs by cutting through the ventrolateral musculature.

There are several fascial membranes plus a retroperitoneal membrane that require transection in order to expose the kidney and permit exteriorization through the skin incision. Once exteriorized the vasculature can be appreciated and ligated using vascular clips or radiosurgery. Starting from the caudal extremity of the kidney the afferent renal veins arising from the caudal vein are ligated. It is also wise to ligate the ureter to avoid the retrograde flow and coelomic contamination of urine stored in the terminal part of the ureters. The kidney is then gently dissected free in a cranial direction taking care to ligate the numerous small renal arteries that arise from the dorsal aorta and enter the dorsal aspect of the kidney. The efferent renal vessels coalesce to form a large renal vein that is ligated at the cranial extent of the kidney.

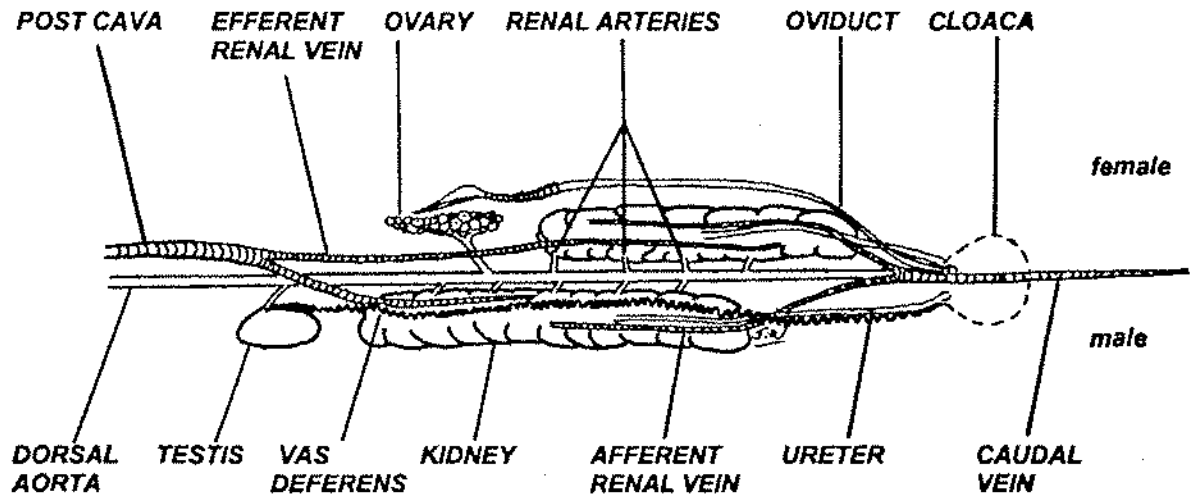
Care should be taken to avoid damaging the closely associated aorta and vena cava. In males attempts to preserve the closely associated vas deferens are usually unwarranted. The adherence of the vas deferens to the peritoneal surface of the kidney generally makes its preservation difficult and the authors (SJD, ML) generally perform a concurrent vasectomy during the nephrectomy procedure. Furthermore, the removal of the kidney also results in a unilateral loss of the sexual segment which is responsible for seminal fluid production. Following nephrectomy, the surgical site should be flushed, particularly if there was any danger of urine/urate contamination, before the soft tissues and skin are closed in a routine manner. Post-operative antibiotics can be employed depending upon the renal pathology evident at surgery, although in cases of non-infectious diseases their use is debatable providing sterility is optimal and there is no urine or urate contamination of the coelomic cavity. The use of post-operative analgesics is to be commended and the authors (SJD, ML) currently prefer carprofen at 4mg/kg im, repeated every 2 - 3 days if necessary.

## REFERENCES

- Beddard, Frank E. 1906. Contributions to the Anatomy of the Ophidia. Proc Zool Soc London, 12-44.
- Bennett RA, Mader DR. 1996. Soft tissue surgery. *In* Mader DR (ed): Reptile Medicine and Surgery. WB Saunders Co, Philadelphia, PA:287-298.
- Chiodini RJ, Sundberg JP, Czikowsky JA. 1982. Gross anatomy of snakes. *Vet Med, S An Clin*, 413-419.
- Fox H. 1977. The Urogenital System of Reptiles. *In* Gans C, Parson T (eds): Biology of the Reptilia. Academic Press, New York, NY:1-157.
- Holtz PH. 1999. The Reptilian Renal Portal System - A Review. *Bull ARAV*, 9(1):4-9.
- Jackson OF, Lawton MPC. 1992. Examination and Diagnostic Techniques. *In* Beynon PH, Lawton MPC, Cooper JE (eds): Manual of Reptiles. Iowa State Univ Press, Ames, IA:32-39.
- Kellicott DS. 1898. The Dissection of the Ophidian. Facsimile Reprint 1938. General Biological Supply House, Inc. Chicago, IL .
- McCracken HE. 1999. Organ location in snakes for diagnostic and surgical evaluation. Chap. 31. Pp243-248. *In* Fowler ME, Miller RE (eds): Zoo and Wild Animal Medicine: Current Therapy. WB Saunders Co, Philadelphia, PA: 747.
- Underwood, Garth. 1967. A Contribution to the Classification of Snakes. Monograph of the British Museum of Natural History, London. 653:1-179.
- Lawton MPC, Stoakes LC. 1992. Surgery. *In* Beynon PH, Lawton MPC, Cooper JE (eds): Manual of Reptiles. BSAVA, Cheltenham, 184-193.

**Figure 1.** Diagrammatic Ventral View of the Snake Urogenital System (Note: colon not shown)

←ANTERIOR



## REFERENCES

- Beddard, Frank E. 1906. Contributions to the Anatomy of the Ophidia. Proc Zool Soc London, 12-44.
- Bennett RA, Mader DR. 1996. Soft tissue surgery. *In* Mader DR (ed): Reptile Medicine and Surgery. WB Saunders Co, Philadelphia, PA:287-298.
- Chiodini RJ, Sundberg JP, Czikowsky JA. 1982. Gross anatomy of snakes. *Vet Med, S An Clin*, 413-419.
- Fox H. 1977. The Urogenital System of Reptiles. *In* Gans C, Parson T (eds): Biology of the Reptilia. Academic Press, New York, NY:1-157.
- Holtz PH. 1999. The Reptilian Renal Portal System - A Review. *Bull ARAV*, 9(1):4-9.
- Jackson OF, Lawton MPC. 1992. Examination and Diagnostic Techniques. *In* Beynon PH, Lawton MPC, Cooper JE (eds): Manual of Reptiles. Iowa State Univ Press, Ames, IA:32-39.
- Kellicott DS. 1898. The Dissection of the Ophidian. Facsimile Reprint 1938. General Biological Supply House, Inc. Chicago, IL .
- McCracken HE. 1999. Organ location in snakes for diagnostic and surgical evaluation. Chap. 31. Pp243-248. *In* Fowler ME, Miller RE (eds): Zoo and Wild Animal Medicine: Current Therapy. WB Saunders Co, Philadelphia, PA: 747.
- Underwood, Garth. 1967. A Contribution to the Classification of Snakes. Monograph of the British Museum of Natural History, London. 653:1-179.
- Lawton MPC, Stoakes LC. 1992. Surgery. *In* Beynon PH, Lawton MPC, Cooper JE (eds): Manual of Reptiles. BSAVA, Cheltenham, 184-193.

**Figure 1.** Diagrammatic Ventral View of the Snake Urogenital System (Note: colon not shown)

←ANTERIOR

